



**PATIENT**

Denali Rose

**SPECIES**

Canine

**BREED**

Shiba Inu

**SEX**

Female Spayed

**AGE**

9 years

**WEIGHT**

22lbs

**INTERPRETED BY**

Maggie Machen Lamy,  
DVM, DACVIM  
(Cardiology)

**IMAGING PERFORMED BY**

Loetitia St-Jacques,  
LVT/RVT

**HOSPITAL NAME**

Mountain View  
Animal Hospital

**REFERRING VET**

Dr. Kalivoda

**INVOICE**

30616

**DATE**

5/4/23

**PRESENTING CLINICAL SIGNS**

History: Grade 1/6 right-sided apical ejection murmur was appreciated. Asymptomatic. History of Cushing's disease. Assess prior to dental.  
-Current medications: Trazodone 50mg prior to stressful events Vetoryl 30mg once daily.

**RADIOGRAPHIC FINDINGS** \*NOTE: Images submitted for supplemental cardiac information only.  
Mild cardiomegaly. No obvious evidence of CHF.

**ELECTROCARDIOGRAPHIC FINDINGS**

A six lead ECG is available at 50mm/s; 10mm/mV. The average heart rate is 100bpm (range 50-150bpm). The rhythm is sinus in origin, with a p for every QRS complex and vice versa. The P wave morphology is positive with a normal dimension. Normal PR. The QRS morphology is positive with normal dimension. MEA is normal. No ectopic beats, pauses or dysrhythmias observed.  
ECG diagnosis: Profound respiratory sinus arrhythmia.

**ECHOCARDIOGRAM FINDINGS**

2D, m-mode, color flow and doppler imaging is available. Mild diffuse thickening of mitral valve leaflets with mild prolapse into the left atrial lumen. Mild to moderate eccentric mitral regurgitation with mild left atrial dilation. Normal MR velocity. Borderline LV dilation with adequate myocardial function. The tricuspid valve appears mildly thickened with trace tricuspid regurgitation. Normal velocity. Normal right atrial and ventricular diameter and morphology indicating no overt evidence of pulmonary arterial hypertension. The pulmonic and aortic valves are normal in morphology and mobility. Normal pulmonic and aortic outflow velocities with laminar flow. No obvious aortic or pulmonic insufficiency. No pericardial or pleural effusion noted. No obvious cardiac masses.

**CARDIAC CHART**

CANINE CARDIAC PARAMETERS	MR VMAX (m/s)	TR VMAX (m/s)	LA/AO (Boon method)	LA/AO (Heart Base; Swe)	FS (%)	EF (%)	EPSS (cm)
NORMAL PARAMETER	4.5-5.5	<2.7	1.3	<1.6	28-40	40-100	<0.6
PATIENT	6.0	2.6	NM	1.4	38	70	NM
CANINE CARDIAC PARAMETERS	HR (BPM)	AV VMAX (m/s)	PV MAX (m/s)	BODY WEIGHT (kg)	LA 2D short axis Base view (cm)	LVIDd Avg; 2D and m-mode short axis (cm)	LVIDs Avg; 2D and m-mode short axis (cm)
NORMAL PARAMETER	50-100	0.7-1.7	0.7-1.6	BELOW	BELOW	BELOW	BELOW
PATIENT	NM	1.5	0.96	10.0	2.3	3.4	2.1
*Normal chamber parameters expressed as a mean value (SD)				3	1.27 (5.3)	2.46 (2.46)	1.36 (5.5)
<b>BODY WEIGHT DEPENDENT PARAMETERS</b>				5	1.40 (4.5)	2.74 (5.2)	1.60 (4.7)
*Note: All measurements based upon multi-modal images and methods. An average value is reported.				10	1.50 (3.8)	3.27 (3.5)	2.06 (3.1)
				15	1.83 (2.0)	3.71 (2.4)	2.43 (2.1)
				20	2.02 (1.9)	4.14 (2.2)	2.80 (2.0)
				25	2.18 (2.4)	4.48 (2.9)	3.10 (2.5)
				30	2.33 (3.3)	4.83 (3.9)	3.39 (3.4)
				35	2.48 (4.3)	5.17 (5.0)	3.69 (4.5)
				40	2.62 (5.2)	5.48 (6.1)	3.96 (5.4)
				50	2.88 (7.1)	6.07 (8.3)	4.46 (7.4)

Adapted from June Boon, Veterinary Echocardiography, 1998  
Rishniw M and Hollis NE, J Vet Intern Med 2000; 14:429-435  
Hansson et al, Vet Rad and Ultrasound 2002  
Bonagura et al. Echocardiography: principles of interpretation, Vet Clin North Am 15:1177, 1995



**PATIENT**

Denali Rose

**SPECIES**

Canine

**BREED**

Shiba Inu

**SEX**

Female Spayed

**AGE**

9 years

**WEIGHT**

22lbs

**INTERPRETED BY**

Maggie Machen Lamy,  
DVM, DACVIM  
(Cardiology)

**IMAGING PERFORMED BY**

Loetitia St-Jacques,  
LVT/RVT

**HOSPITAL NAME**

Mountain View  
Animal Hospital

**REFERRING VET**

Dr. Kalivoda

**INVOICE**

30616

**DATE**

5/4/23

**INTERPRETATION OF THE FINDINGS & FURTHER RECOMMENDATIONS**

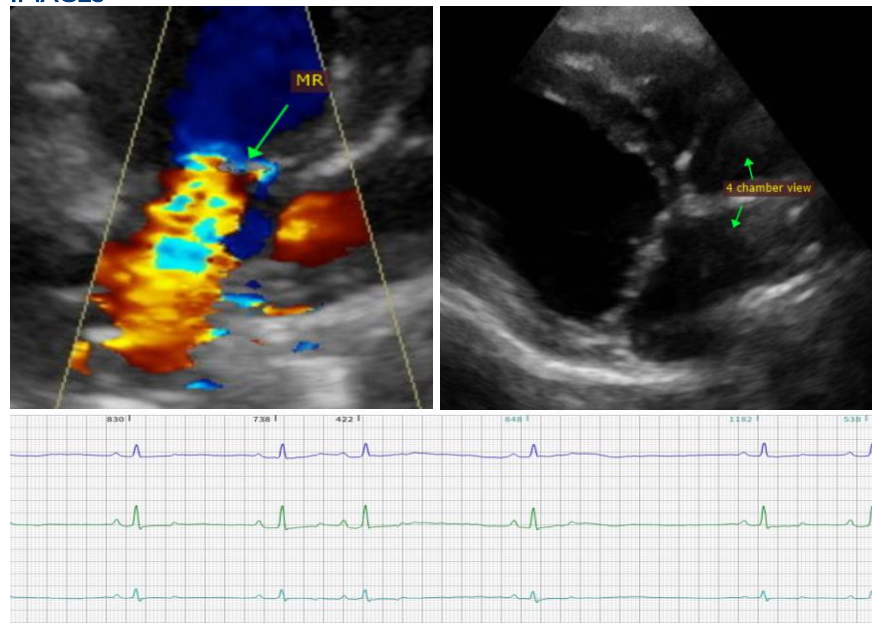
Chronic degenerative valve disease causing mild to moderate mitral and trace tricuspid regurgitation. Lack of significant left atrial enlargement indicates the current risk for complication is low. No concurrent issues such as systolic dysfunction or pulmonary hypertension are noted in this study. The ECG is unremarkable with a profound respiratory sinus arrhythmia. This is presumably due to high vagal tone +/- sedation.

In an asymptomatic dog with no significant left atrial enlargement, no cardiac medications are clearly indicated. Assessment of progression in the future will help predict long term prognosis, which is highly variable at this stage. Omega fatty acid supplementation and mild salt restriction may be of some long-term benefit. Monitor for development of a cough, labored breathing, exercise intolerance or collapse episodes.

Anesthetic risk is considered mild if needed. Cardiac protective drug choices (opioid/benzodiazepine premedication, propofol or alfaxalone induction, isoflurane gas) are recommended. Pre-oxygenate for 5-10 minutes prior to induction. Monitor for arrhythmias, hypotension, and hypoxia both intra and post-operatively and intervene as necessary. Mild IV fluid restriction is recommended to avoid fluid overload. Avoid heart rate stimulating drugs such as atropine unless clinically indicated.

Recommend conservative monitoring with a recheck echocardiogram in 6 months, sooner if any development of clinical signs.

**IMAGES**





**PATIENT**

Denali Rose

The information and recommendations provided are based on the images presented by the referring veterinarian. No evaluation can be communicated regarding pathology that was not visible in the image/video clips provided.

**SPECIES**

Canine

Thank you for this referral. This report was generated using transcription software, and minor dictation errors may be present. If the clinical or image interpretation does not parallel your findings or if I can be of any further assistance, please contact me.

**BREED**

Shiba Inu

Maggie Machen Lamy, DVM  
Diplomate of the American College of Veterinary Internal Medicine (Cardiology)  
info@sonopath.com

**SEX**

Female Spayed

**AGE**

9 years

**WEIGHT**

22lbs

**INTERPRETED BY**

Maggie Machen Lamy,  
DVM, DACVIM  
(Cardiology)

**IMAGING PERFORMED BY**

Loetitia St-Jacques,  
LVT/RVT

**HOSPITAL NAME**

Mountain View  
Animal Hospital

**REFERRING VET**

Dr. Kalivoda

**INVOICE**

30616

**DATE**

5/4/23